

**C-TECH**  
IMPLANT

# **Removable dentures retained by C-Tech implants**

**Kristian Gerga**

**DDS, Private practice, Banatsko Novo Selo,  
Serbia**

**Case report**

# Short Description

Male patient, age 33.

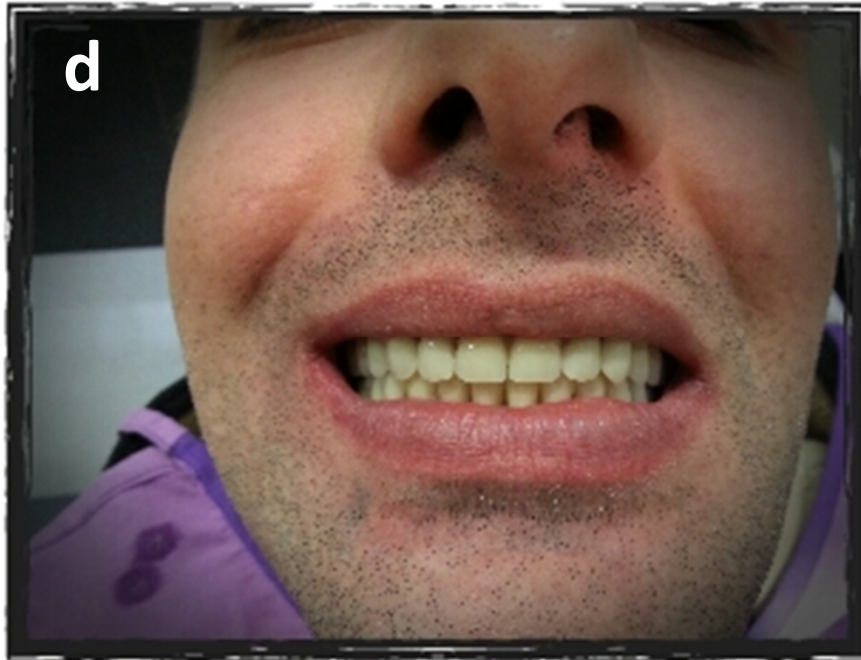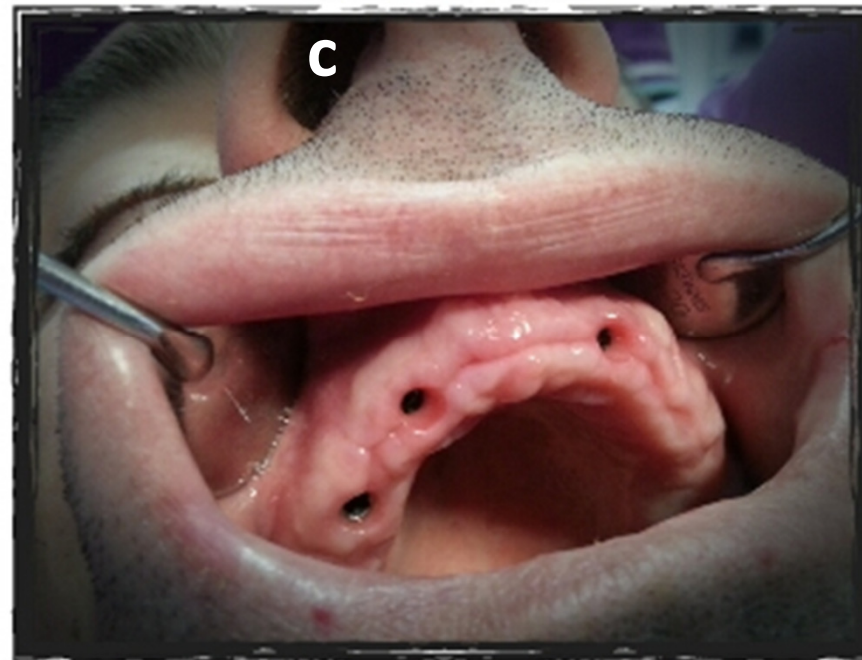
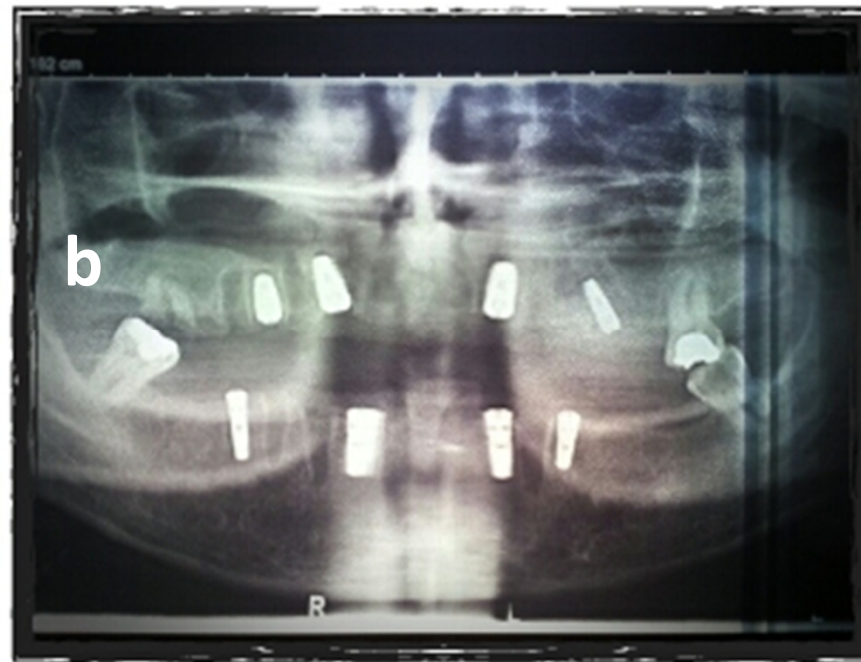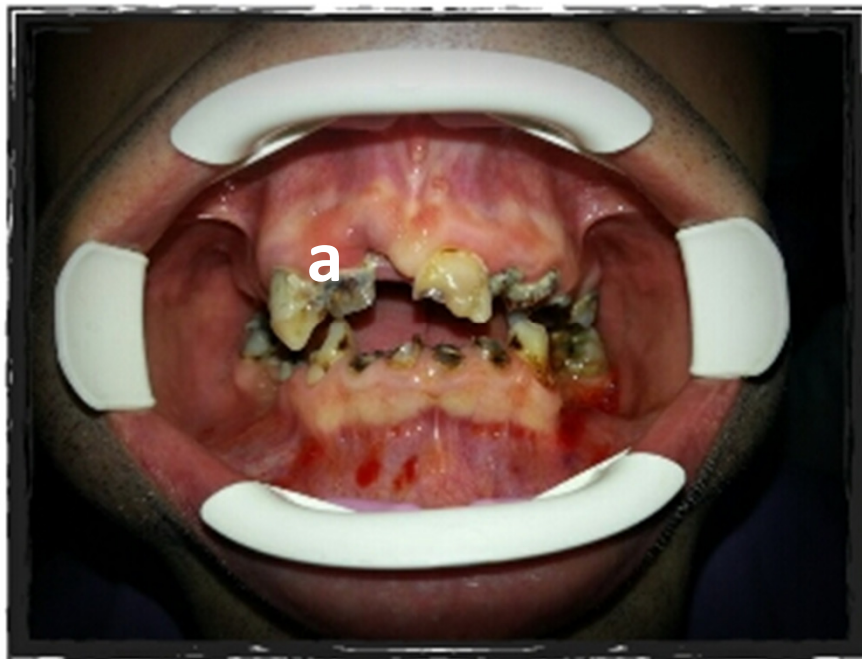
In the first session all teeth in upper and lower jaw were extracted.

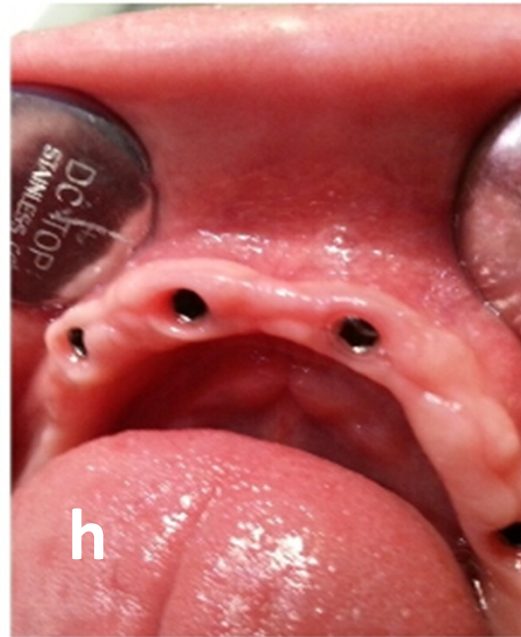
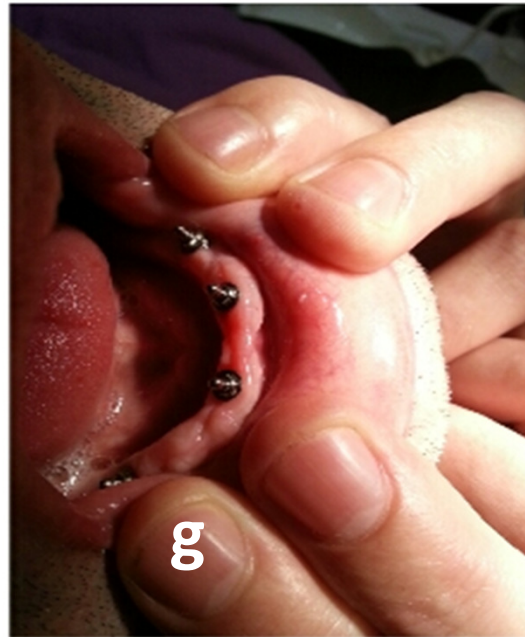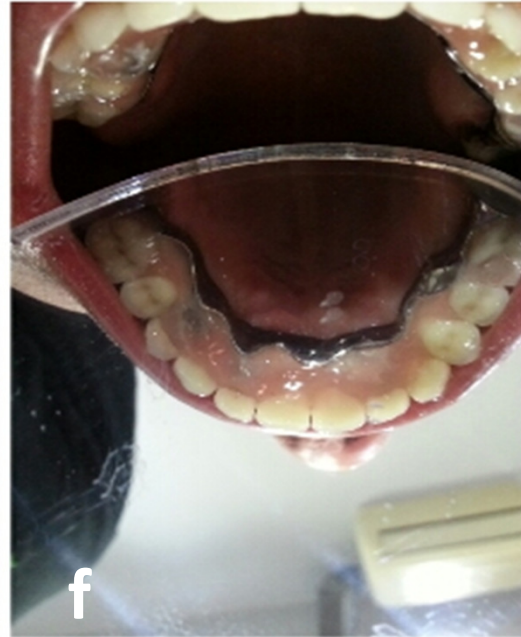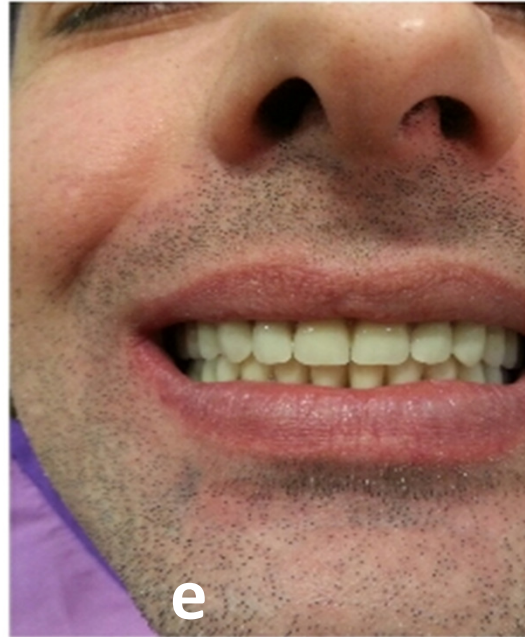One Stage procedure has been performed with 4 GL C-Tech Implants in upper jaw and 1 GL C-Tech and 3 EL C-Tech in lower jaw.

In the same session were placed PEEK Healing Abutments.

Prosthetic procedure with C-Tech O-Ball Attachment System was performed 6 months later.

Removable dentures retained by implants have been made in mandible and maxilla.







# Picture description

a- Preoperative status

b- Implants (Orthopantomograph)

c, h- Gingiva after 6 months of healing period

d, e, f- Finale result- rehabilitation with implant retained removable dentures

g- O-ball Abutments

# Material

- GL Implants
- EL Implants
- Peek Healing Abutments
- O-ball Attachment System



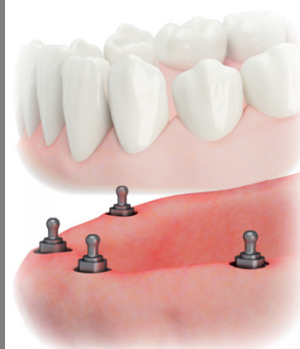**GL Implant**



**EL Implant**



**Peek Healing  
Abutments**

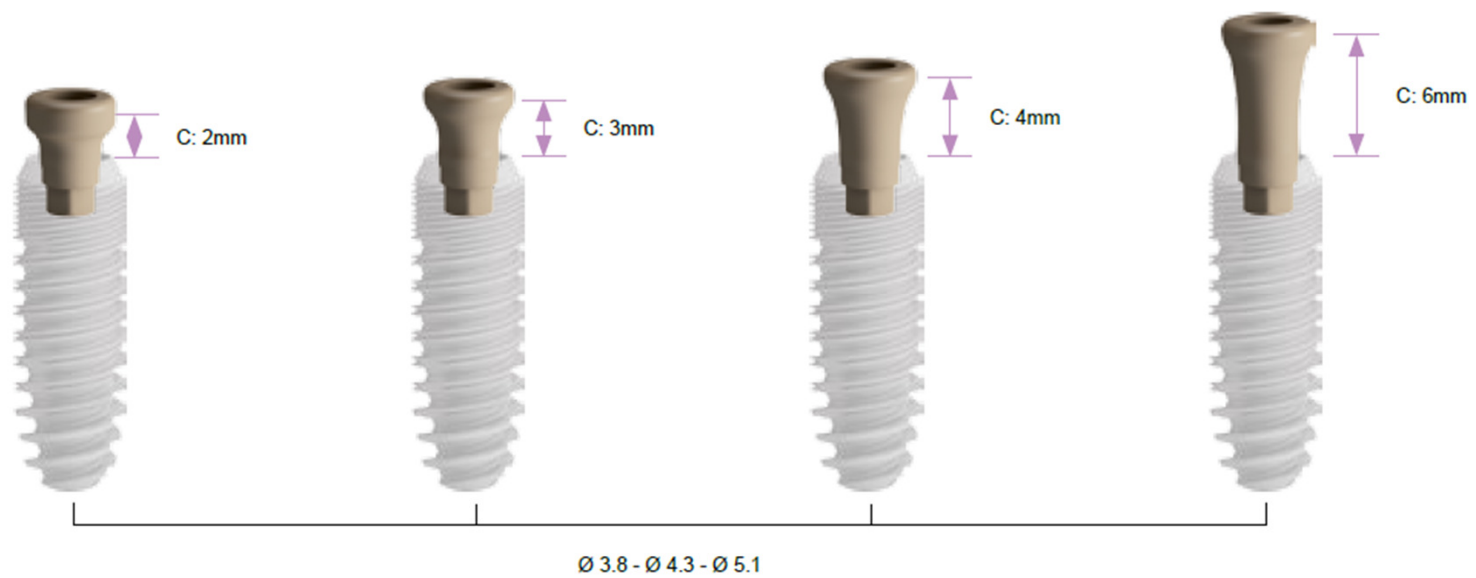


**O-ball  
Attachment  
System**

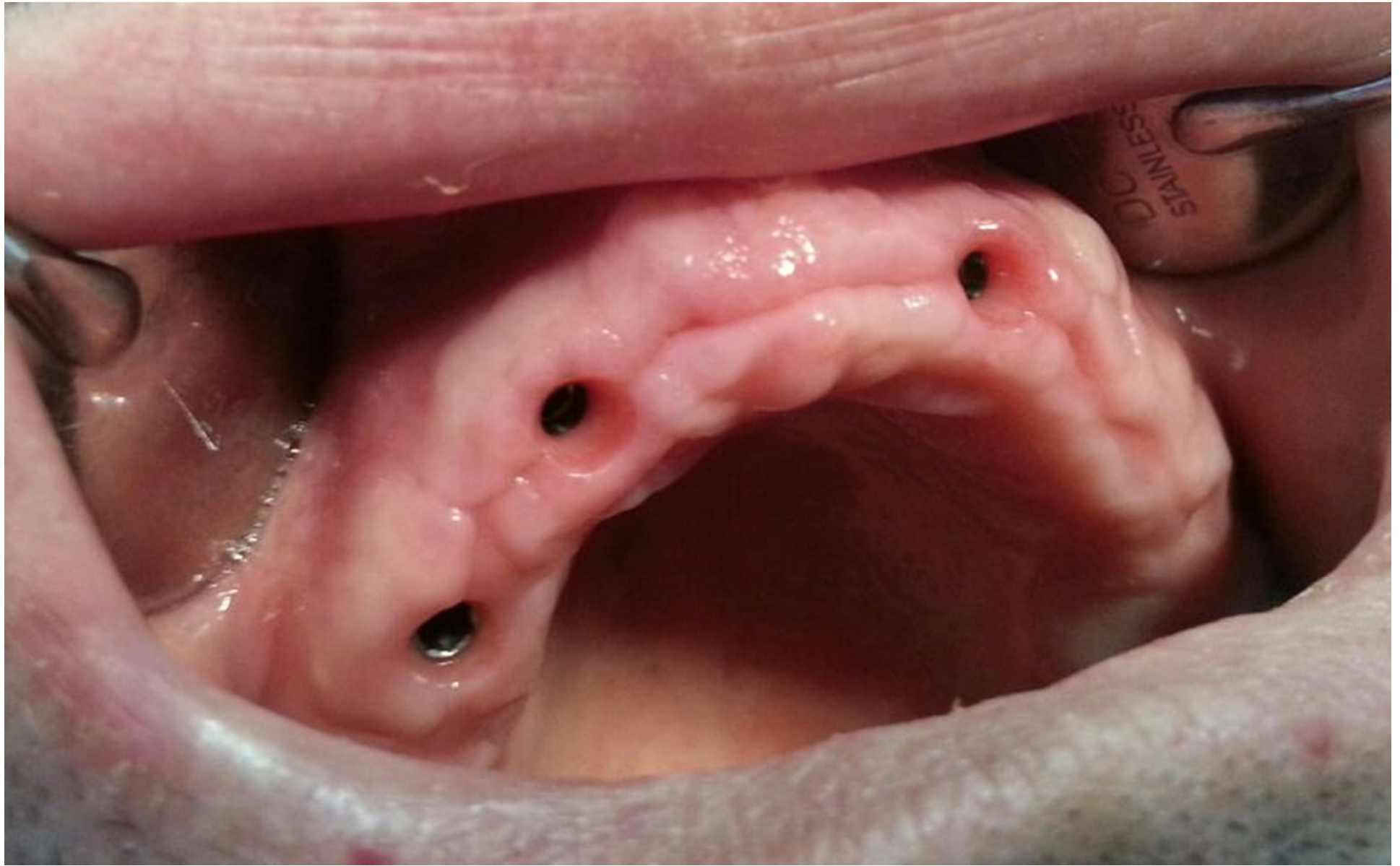


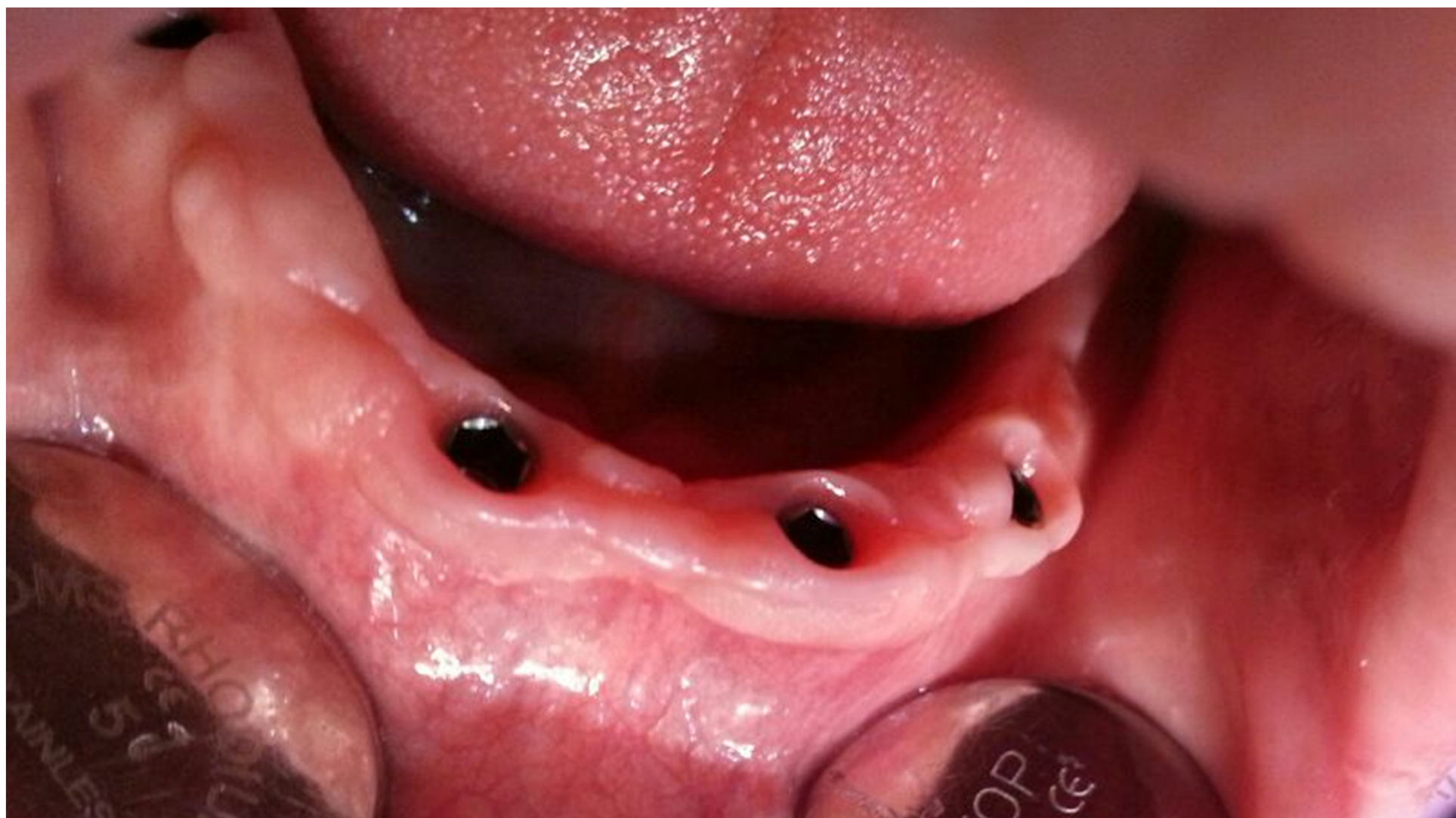
## Peek Healing Abutments



- Accomodates subcrestal implant seating
- Uses 1.25 prosthetic driver
- Tightening torque 15 Ncm
- Material: PEEK
- Includes prosthetic screw









**C-TECH**  
IMPLANT